

New Syndrome

A Novel Form of Lethal Microcephaly With Simplified Gyral Pattern and Brain Stem Hypoplasia

Anna Rajab,^{1*} M. Chiara Manzini,² Ganeshwaran H. Mochida,^{2,3}
Christopher A. Walsh,^{2,4} and M. Elizabeth Ross⁵

¹Genetic Unit, DGHA, Ministry of Health, Muscat, Sultanate of Oman, Oman

²Department of Neurology and Howard Hughes Medical Institute,

Beth Israel Deaconess Medical Center and Harvard Medical School, Boston, Massachusetts

³Pediatric Neurology Unit, Department of Neurology, Massachusetts General Hospital, Boston, Massachusetts

⁴Division of Genetics, Children's Hospital, Boston, Massachusetts

⁵Laboratory of Neurogenetics and Development, Weill Medical College of Cornell University, New York, New York

Received 2 March 2007; Accepted 6 June 2007

We report on four patients from the same family affected by a lethal form of autosomal recessive microcephaly of prenatal onset. Symptoms include low birth-weight and length with disproportionately small head, fetal distress, apnea, seizures and facial features reminiscent of Amish microcephaly and Bowen–Conradi syndrome. Brain imaging revealed a simplified gyral pattern with normal to slightly thinned cortical gray matter, thin corpus callosum, mild brainstem and cerebellar hypoplasia. No abnormalities of the internal organs, eye, or skeleton, and no striking dysmorphic facial features were found to be associated with this syndrome. All patients died within hours to weeks after birth following

severe apnea attacks and central hypoventilation. Recessive primary microcephaly with lethality in early infancy is rarely reported. The patients described here do not resemble any other published cases of such clinical severity and the locus for the only reported early lethal microcephaly gene found in Amish families was excluded. Therefore, this appears to be a distinct genetic cause of lethal microcephaly.

© 2007 Wiley-Liss, Inc.

Key words: lethal microcephaly; simplified gyral pattern; fetal distress; apnea; autosomal recessive inheritance

How to cite this article: Rajab A, Manzini MC, Mochida GH, Walsh CA, Ross ME. 2007. A novel form of lethal microcephaly with simplified gyral pattern and brain stem hypoplasia. *Am J Med Genet Part A* 143A:2761–2767.

INTRODUCTION

Microcephaly is defined as small head size characterized by occipito-frontal circumference (OFC) at least 2 standard deviations (SD) below the mean. It is a common developmental defect, which can have either prenatal or postnatal onset. It is anatomically, clinically, and etiologically a heterogeneous disorder [Mochida and Walsh, 2001]. Microcephaly has been reported in numerous syndromes with a large spectrum of clinical presentations, inheritance patterns, lifespan, degree of psychomotor abnormalities and variety of associated anomalies including various inborn errors of metabolism [Mochida and Walsh, 2001; Dobyns, 2002; Woods, 2004]. It can be of environmental origin and it has been associated with different teratogenic agents [Woods, 2004].

While microcephaly is often observed in multi-organ genetic syndromes, isolated microcephaly is not as common [Mochida and Walsh, 2001; Woods,

2004]. Primary microcephaly is detectable prenatally, and several autosomal recessive forms of primary microcephaly have been described with varying severity and clinical presentation. Microcephaly *vera* is characterized by normal cerebral cortical thickness, normal or mildly disrupted gyral pattern, mild developmental delay and moderate mental retardation [Mochida and Walsh, 2001]. At the other end of the spectrum, Amish lethal microcephaly presents extremely profound microcephaly (less than -6 SD), agyria and hypoplasia of the cerebellum and pons.

Anna Rajab and M. Chiara Manzini Contributed equally to the work.
Grant sponsor: NIH; Grant numbers: PO1NS048120, R37-NS35129.

*Correspondence to: Dr. Anna Rajab, Consultant Clinical Geneticist, Genetic Unit, DGHA, Ministry of Health, P.O. Box 880, Muscat 113, Sultanate of Oman, Oman. E-mail: drarajab@omantel.net.om

DOI 10.1002/ajmg.a.31955

Affected children are unresponsive to light and noise, and usually die by 6 months of age because of metabolic acidosis, associated with 2-ketoglutaric aciduria [Kelley et al., 2002].

Smaller head size is usually correlated with reduced brain growth [Mochida and Walsh, 2001; Cox et al., 2006]. Brain development is a complex process determined by multiple factors regulating cell proliferation, migration and neuronal circuit formation. Primary microcephaly is first detectable during pregnancy when the brain fails to grow as neurons are generated, suggesting that defects in neuronal proliferation are the principle cause of this malformation. As expected, the analysis of families affected by autosomal recessive primary microcephaly has led to the identification of genes involved in the regulation of neuronal mitosis [Cox et al., 2006]. *ASPM* (abnormal spindle-like, microcephaly-associated), *CDK5RAP2* (cyclin-dependent kinase 5 regulatory subunit-associated protein 2) and *CENPJ* (centromere protein J) are all important for the correct assembly of the mitotic spindle [Bond et al., 2002, 2005], while microcephalin regulates chromosome condensation in prophase [Jackson et al., 2002]. The Amish lethal microcephaly gene, on the other hand, encodes for a mitochondrial deoxynucleotide carrier (*DNC*), and it is associated with increased cell death in the developing brain [Rosenberg et al., 2002]. Mitochondrial dysfunction explains the accumulation of α -ketoglutarate and the metabolic defects in the patients, but it is not clear how perturbation of DNC function causes such severe reduction in the number of neurons. Functional studies of the identified genes and further investigation of the genetic causes of autosomal recessive microcephalies will help define the mechanisms responsible for the control of brain size.

The emergence of nuclear magnetic resonance imaging (MRI) opened a new avenue to study morphological and structural brain anomalies. Microcephaly is evident upon physical examination, but the spectrum of brain malformations associated with different forms of microcephaly can only be diagnosed by imaging the brain. The combination of clinical and radiological findings has proven a powerful approach in grouping patients for molecular studies and gene identification [Mochida and Walsh, 2004; Barkovich et al., 2005].

Here, we present a clinical study of four patients from a consanguineous couple with a lethal form of microcephaly characterized by simplified gyral pattern and small corpus callosum, brainstem, and cerebellum. Most patients died in the neonatal period and the longest survival did not exceed 40 days. Clinical and radiological features are not consistent with any previously described syndrome, indicating that this is a novel form of lethal microcephaly.

PATIENTS AND METHODS

Clinical Studies

The parents and four affected children in one Omani family were examined by A.R. and the brain imaging results were reviewed independently by M.E.R, G.H.M., and C.A.W.

Microsatellite Marker Analysis

Genomic DNA was purified from Patient 4 after obtaining informed consent in accordance with protocols approved by the Institutional Review Board of Children's Hospital and Beth Israel Deaconess Medical Center, and the Office of Human Research Protection. Peripheral blood was subject to lymphocyte separation using Lymphocyte Separation Medium (Organon Technica, Durham, NC) and DNA was extracted from lymphocytes using commercial kits (Qiagen, Valencia, CA). Highly polymorphic microsatellite markers associated with the Amish lethal microcephaly (MCPHA) locus on chromosome 17q25 were chosen from the Marshfield database in the UCSC Genome Browser (<http://genome.ucsc.edu/>). Fluorescently labeled PCR primers (ABI, Foster City, CA) were purchased for each marker and used to amplify the patient DNA sample using standard conditions. PCR products were resolved on an ABI 3130xl Genetic analyzer. Alleles were assigned using the Genotyper software package (ABI).

RESULTS

The parents belong to a large tribal unit from Oman and are first cousins. They are both healthy with no family history of brain malformation. Occipitofrontal circumference (OFC) was 53 cm (10th centile) for both parents. At the time of the first pregnancy, the mother was 17 years old and the father was 20. The mother did not receive prenatal vitamin supplementation before the first pregnancy, but was administered prenatal vitamins prior to all successive conceptions. She had no history of any medication, infection or irradiation exposure during any of the pregnancies. The couple had five children: four affected by lethal microcephaly (Patients 1–4, below) and one unaffected sibling born after Patient 4.

Patient 1

Ultrasound serial scans during pregnancy showed inappropriately small biparietal diameter (BPD) measurements. The proband was a male, delivered at 37 weeks gestation by cesarean because of fetal distress. Birth weight was 2.35 kg (5th centile), OFC 29 cm (<3rd centile, -3.5 SD below the mean,

[Fenton, 2003]), length 44 cm (3rd centile, -1.5 SD) and chest circumference 29 cm (50th centile, mean for gestational age). Apgar scores were 1 at 1 min and 6 at 5 min. The newborn had a disproportionately small head compared to normal size shoulders and normal body proportions. The anterior fontanelle was almost fused. The forehead was narrow, short and sloping, and the anterior hairline was low. There were bitemporal dimples and areas of scalp hair growth over the temples in close proximity to distal ends of the brows. The patient had irregular respirations and required oxygen. No intubation was attempted. He died at the age of 1 hr and 40 min because of poor respiratory drive and central apnea. Blood gases were normal after face-mask oxygenation for 5 min on 3 occasions. Chest radiograph and skeletal survey were unremarkable.

Patient 2

Patient 2 was a younger sister of Patient 1. Head size was closely monitored during pregnancy and it was found to be falling behind from the 20th week of pregnancy. In the third trimester BPD measurements were -3.5 SD below the mean. The patient was born by normal vertex delivery at term. Birth weight was 2.6 kg (3rd centile), OFC 29 cm (<3 rd centile, -3.5 SD below the mean), length 43 cm (<3 rd centile, -2 SD) and chest circumference 29 cm (10th centile, -1 SD). Apgars were 6 at 1 min and 8 at 5 min after birth. The facial and body appearance was similar to Patient 1. There were no joint contractures to suggest oligohydramnios. There were irregular respirations and apnea attacks, but no abnormalities of heart or lungs were detectable on clinical examination. The baby required face-mask oxygen and after bagging, blood gases were within normal range. Chest radiograph and electrocardiogram were entirely normal. She died at the age of 6 hr following a prolonged apnea attack.

Patient 3

The BPD monitored on fetal ultrasound during the third pregnancy was -4 SD below the mean at 22 weeks of gestation and continued to lag on subsequent sonograms. Cesarean was performed at 36 weeks gestation because of the deterioration of the fetal movements and abnormal cardiotocogram (CTG). The female baby weighed 2.05 kg (5th centile), had an OFC of 27 cm (<3 rd centile, -3.5 SD below the mean) and length 44 cm (9th centile, -1 SD). Apgars were 2 at 1 min and 6 at 5 min, respiratory efforts were adequate and blood gas parameters were maintained with head box oxygen. The baby had a normal body habitus and normal chest size, which contrasted with disproportionately small head size. The anterior fontanelle was almost closed. The forehead was flat, narrow and short with

low anterior and temporal hairline. There were temporal dimples and orbital ridges appeared prominent. The nose appeared large but had average length of 1.7 cm, which is proportionate to the body length at this developmental stage [Siebert, 1986]. There was no evidence of pulmonary infection on chest X-ray examination. Ultrasound examination of the abdomen and an echocardiogram were normal.

Jitteriness was noticed in the first day of life. Seizures, poor responsiveness to stimuli, inactivity, apnea, truncal hypotonia, marked hyperreflexia and ankle clonus became evident from the first week of life. The patient startled to loud noises and had complete visual inattention. She was not able to breastfeed sufficiently and was given supplementary tube feeds, but she failed to thrive. No biochemical abnormalities were found, and ammonia, lactate, serum amino acids and urinary organic acids were all reported as normal.

A computerized tomogram (CT) of the head revealed simplified gyri with shallow sulci and normal to thinned cortex, suggesting microcephaly with simplified gyri (MSG) [Dobyns, 2002]. There was thinning of the corpus callosum that was apparent anteriorly (Fig. 1B). The extra-axial spaces were generous. The brainstem was only mildly hypoplastic compared with the cortex and there was cerebellar hypoplasia including the vermis (Fig. 1C, arrow) that was proportional to the cortical microcephaly. Apneic attacks increased in frequency after the first month. Repeated blood counts, urinalysis, bacterial cultures of urine, blood and surface swabs were all normal. The patient died at the age of 40 days, likely because of central hypoventilation.

Patient 4

The fourth pregnancy was uneventful, but head size of the foetus measured 25 cm (-2 SD below the mean) during the first visit at 30 weeks of pregnancy. A female child was born by emergency cesarean at 34 weeks because of fetal distress. Apgars were 7 at 1 min and 8 at 5 min. Birth weight was 2.35 kg (55th centile), OFC 29 cm (8th centile, -1.5 SD below the mean), length 43 cm (15th centile, -1 SD) and chest circumference 28 cm (50th centile, mean for gestational age). The baby had similar facial features to Patients 1–3 with a disproportionately small cranium and normal body proportions (Fig. 2A,B). Nasal length was 1.8 cm. There was also a sacral dimple. No skeletal anomalies noted on radiological survey. Echocardiogram and chest X-ray were unremarkable; abdominal ultrasound did not reveal any liver or renal abnormalities. Arterial blood gases, blood counts, blood cultures, serum electrolytes, urinalysis, serum amino acids and urinary organic acids were all normal.

Paucity of movements, jitteriness on stimulation and attacks of apnea were observed from the first

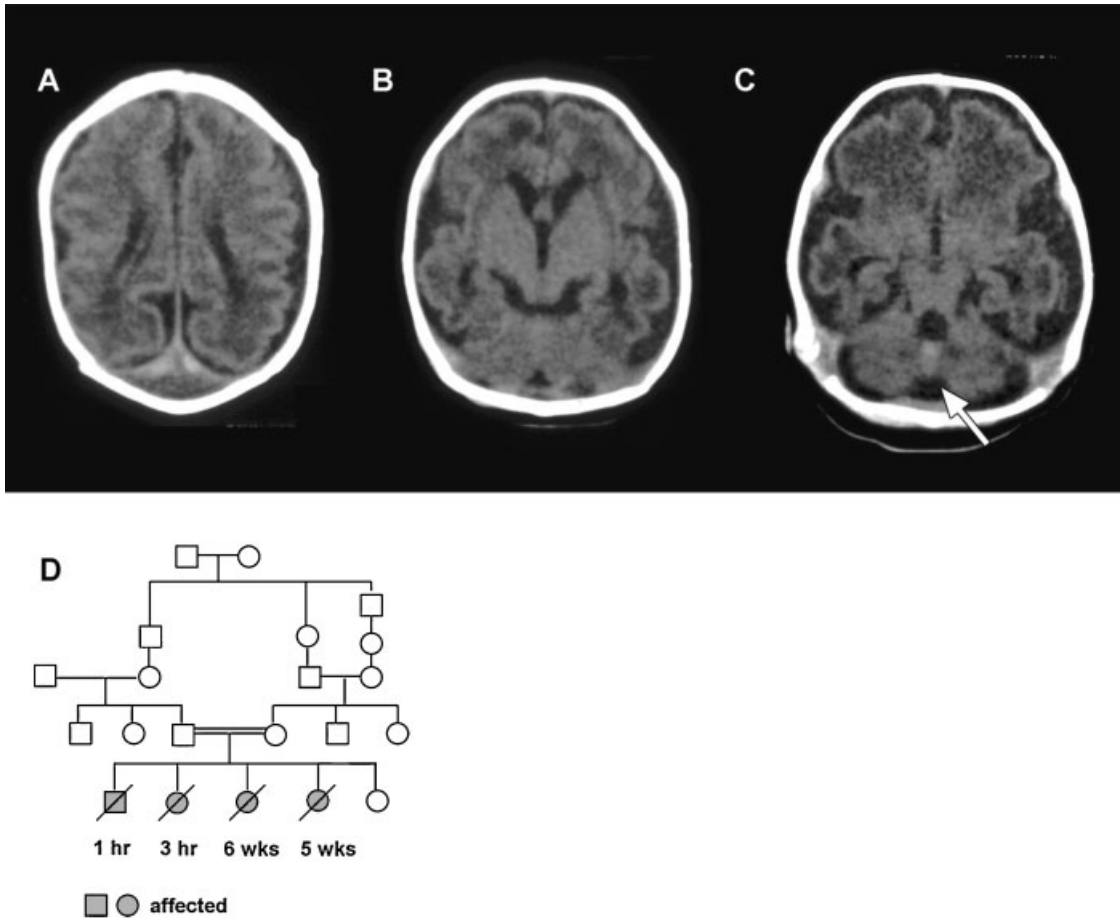


FIG. 1. Neuroimaging and pedigrees from a family with lethal microcephaly. **A–C:** CT images of Patient 3 reveal a simplified gyral pattern with normal to thinned cortical gray matter and mildly enlarged extra-axial space (A). Anteriorly (B) the corpus callosum is significantly thinned. Brainstem hypoplasia is mild compared to the reduced cortical volume while the cerebellar hemispheres and vermis (C, arrow) are small but proportional to the cerebral cortex. **D:** The simplified pedigree from the Omani family shows four affected siblings, all of whom died by 7 weeks of age. Age of death for each child is listed below the pedigree.

day of life. Brisk knee jerks and ankle clonus could be elicited at the age of 1 week. There was no response to visual stimuli, but there was response to auditory stimulation. CT scan was similar to Patient 3. Head

growth was reduced with only 1 cm increase in OFC in the first 7 weeks of postnatal life.

The baby was inactive and fed poorly. Breastfeeding was attempted but was insufficient and supplementary tube feeds were required. The patient became ill with gasping respirations and apnea at the age of 25 days. Aspiration pneumonia was diagnosed on chest radiogram. Parenteral antibiotics and supplementary oxygen were administered. Apnea attacks became more frequent and prolonged. After bagging with oxygen blood gases were normal. It was decided not to ventilate the patient and she died at the age of 35 days. Upon radiological analysis, pulmonary changes due to pneumonia were not found to be extensive enough to cause demise. Central hypoventilation was the likely cause of death.

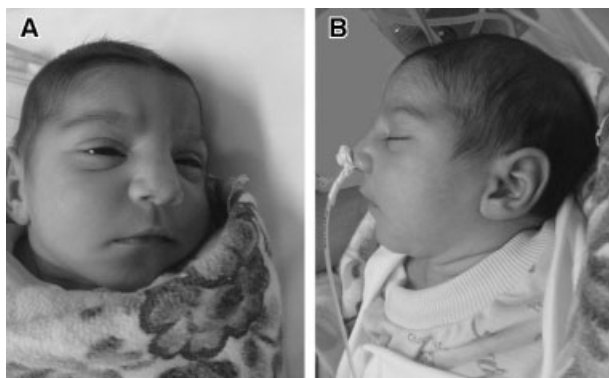

FIG. 2. Physical appearance. Patient 4 in three-quarter (A) and side profile (B) shows a disproportionately small neocranium compared with normal facial features, making ears and nose appear large. Low hairline, sloping forehead, and temporal hollowing are consequences of the disproportion between calvarium and skull base.

Exclusion of the MCPHA (DNC) Locus

The only known gene responsible for lethal microcephaly was mapped in an Amish kindred to a locus on chromosome 17 (MCPHA, 17q25;

[Rosenberg et al., 2002]). The lack of metabolic acidosis in the patients described here suggests that this form of lethal microcephaly may have a different cause than Amish microcephaly, which is associated with mitochondrial failure. However, to exclude that these children had a different form of the same syndrome, we analyzed the MCPHA locus. Since the parents are first cousins, it is expected that the founder mutation, originated in a common ancestor, will be transmitted in homozygosity to the affected children [Lander and Botstein, 1987]. Genomic DNA was obtained from Patient #4 and two highly polymorphic microsatellite markers flanking the *DNC* gene, D17S1807 and D17S785, were tested. Both markers were present in heterozygosity in Patient #4 (D17S1807: allele1 = 264, allele2 = 274; D17S785: allele1 = 183, allele2 = 189), indicating that *DNC* is not associated with this disorder.

DISCUSSION

The four patients described in this article had a lethal form of microcephaly of prenatal onset, with OFCs at birth measuring -1.5 to -3.5 SD for gestational age. One baby (Patient #4) had a birth OFC of -1.5 SD with birth weight and chest circumference in the 50th centile, brain CT findings of MSG and succumbed by 6 weeks. This relatively larger OFC of the four cases may reflect the fact that this baby was the most premature of the live births and the head size would continue to fall off the curve, as indeed it did in the neonatal period despite supplemental tube feeding. Reduced OFC was detectable in our patients as early as the 20th week of pregnancy on fetal ultrasound examination.

Reduced fetal movements were noted by the mother in all affected pregnancies. Fetal distress with CTG abnormalities were detected in three monitored deliveries and were indication for deliveries by caesarean. It is uncertain if intrauterine death was the possible outcome in Patients #1, 3, and 4, if caesarean had not been performed. The birthweight

for all of these patients was small to average for age (5th to 55th centile). They had a similar appearance with small neocranium, short sloping forehead, low anterior and temporal hairline, small glabellar angle and relatively large nose. Since it is possible that next to a sloping forehead and small OFC the nose may appear larger and the glabellar angle smaller, the nasal length was measured in two of our patients (Patients #3 and 4) and was found to be proportionate to body length [Siebert, 1986]. Similarly, the head appeared particularly small in comparison with an average chest size and normal body proportions (Table I).

All four patients had failure of adaptation after delivery, irregular respirations, apnea attacks and jitteriness from the first days of life. Flexions of the limbs, head jerking and often mouth and limb twitching was observed. They all required face-mask oxygen and died within the first hours, days, or weeks of life following apnea attacks and central hypoventilation. Lung function proved to be satisfactory in all patients and early demise in our patients could not be attributed to pulmonary causes as oxygen and CO₂ exchange were easily supported with facemask O₂ or bagging. Therefore, brain stem hypoplasia and malfunction of respiratory centers could be the cause of recurrent apnea. Substantial clinical evaluation did not find evidence of skeletal anomaly, liver or renal abnormality, or evidence of a defect in metabolic homeostasis or amino aciduria.

Brain imaging is difficult to obtain in these children. They survive for a short period of time, during which they are clinically unstable due to apneic episodes and the risk of further depressing respirations precludes the sedation required for CT or careful MRI study. CT images that are available on two of our patients (Patients #3 and #4), and share similar features. These include a simplified pattern of cortical gyri with normal or slightly reduced thickness of the cortical gray matter. There is thinning of the corpus callosum, especially anteriorly and cerebellar volume reduction, including the vermis that is proportional to the cortical microcephaly. The brainstem is also reduced in volume but to a lesser

TABLE I. Clinical Features in Four Patients (Three Females and One Male)

| Patients | 1 | 2 | 3 | 4 |
|--|-------------|---------|---------|---------|
| Gestation age | 37 | 38 | 36 | 34 |
| Birth-weight | 2,350 g | 2,600 g | 2,050 g | 2,350 g |
| Length at birth | 44 cm | 43 cm | 44 cm | 43 cm |
| Small OFC/chest circumference ratio | + | + | + | + |
| Microcephaly | 29 cm | 29 cm | 27 cm | 29 cm |
| Small neocranium compared to facial structures | + | + | + | + |
| Sloping narrow forehead | + | + | + | + |
| Low frontotemporal hairline | + | + | + | + |
| Prominent nose | + | + | + | + |
| Inactivity | + | + | + | + |
| Apneic attacks | + | + | + | + |
| Seizures | ? | ? | + | ? |
| Days survived | 1 hr 40 min | 6 hr | 40 days | 35 days |

degree than the reduced overall brain size. The extra-axial spaces around the brain are generous, but not strikingly enlarged. This indicates that the growth of the brain is at least relatively parallel to the cranial growth and suggests a primary problem with neural proliferation or combination of proliferation and cell death rather than excessive neural apoptosis as the cause of microcephaly here [Woods, 2004].

We cannot absolutely exclude an unknown inborn error of metabolism that was not corrected by maternal-fetal blood exchange or circulation and that produced a defect of neuronal proliferation and patterning. However, most patients with inborn errors of metabolism present with severe metabolic imbalances and microcephaly is typically postnatal rather than congenital [Dobyns, 2002]. Our metabolic screens found no evidence of pancreatic, hepatic or renal system failure, aminoaciduria or acidosis beyond that readily corrected with respiratory support for apneic episodes.

Severe microcephaly ($OFC \leq -3$ SD below the mean), such as observed in these patients is more likely to have a genetic origin, as microcephaly attributable to the intrauterine environment, for example, following maternal diabetes, drug exposure or intrauterine infection, is typically less pronounced (-2 SD below the mean) [Dobyns, 2002]. When compared with the reports of autosomal recessive microcephaly with simplified gyral (MSG) pattern available in the literature, these patients appear clearly distinct. Some features observed in the patients described here resemble those in Bowen–Conradi Syndrome (BCS), a lethal autosomal recessive syndrome first described by Bowen in the Hutterite community [Bowen, 1990] and more recently reported in India [Gupta and Phadke, 2001]. However, while the BCS patients encountered by Bowen [1990] and Lowry et al. [2003] presented with microcephaly with micrognathia and low birth weight, they were also characterized by overlapping fingers, joint contractures and an average survival to 13 months [Hunter et al., 1979; Bowen, 1990; Lowry et al., 2003]. Early demise and the absence of joint contractures in our patients, combined with the normal appearance of the brain on CT scans of 13 examined BCS patients [Lowry et al., 2003], suggest that BCS represents a different condition from our patients.

Peiffer et al. [1999] described microcephaly in six related children with onset of seizures at 2–4 months of age and mental deficiency with similarity in phenotypic appearance, similar head size at birth and joint contractures. However, none of our patients had joint contractures and all cases reported by Peiffer had better survival in the first year of life and half reached adult age.

Sztriha et al. [2005] reported a single case of extreme microcephaly with MRI abnormalities of cortex, pontocerebellar dysplasia and partial agen-

esis of corpus callosum. However, Sztriha's patient had an apparently different condition as he lived at least a year and brain imaging was distinct from our patients. MR brain images in the Sztriha report showed a cortex with variable thickness (normal in some areas and significantly thickened in others) consistent with a neuronal migration defect and there was more severe midline cerebellar hypoplasia.

Like our patients, children with Amish lethal microcephaly (MCPHA) [Kelley et al., 2002] also died in early infancy. However, brain images of our patients differ from the single published MRI associated with mutation in the deoxynucleotide carrier gene (*DNC*) [Kelley et al., 2002; Rosenberg et al., 2002]. That image was quite distinct from the present cases in that there was only a thin remnant of cerebral cortex and marked cerebellar hypoplasia with a relatively preserved brainstem and diencephalon. Moreover, our patients did not have metabolic derangements characteristic of MCPHA and the survival in the reported Amish cases was better than for our patients. Most importantly, our patients did not map to the same locus as Amish lethal Microcephaly, ruling out mutation in the *DNC* gene as a possible cause of microcephaly in these Omani children.

The incidence of congenital lethal microcephaly is difficult to assess and may be more prevalent than currently appreciated. This condition may escape accurate reporting due to third trimester or neonatal lethality and/or the challenges of investigating critically ill newborns. Indeed, we have observed another five patients with a similar phenotype, but these could not be included in this study because investigations were incomplete. The selection of patients for molecular studies who survive for a very short time poses challenges for obvious reasons. The diagnosis of congenital lethal microcephaly can be reached by exclusion of other metabolic and syndromic causes, neuroimaging and comparison of neurodevelopment and growth patterns with normative data.

In conclusion, we described novel form of lethal microcephaly of prenatal onset with simplified gyri and unique set of brain abnormalities detectable on MRI, which does not map to Amish locus.

ACKNOWLEDGMENTS

The authors would like to thank the family for their participation in this study; Bernard Chang for assistance in reviewing the radiological findings, and Christina Austin for technical help. This work was supported by NIH grants PO1NS048120 (MER) and R37-NS35129 (CAW). CAW is an Investigator of the Howard Hughes Medical Institute. GHM is supported by the NARSAD Young Investigator Award.

REFERENCES

- Barkovich AJ, Kuzniecky RI, Jackson GD, Guerrini R, Dobyns WB. 2005. A developmental and genetic classification for malformations of cortical development. *Neurology* 65:1873–1887.
- Bond J, Roberts E, Mochida GH, Hampshire DJ, Scott S, Askham JM, Springell K, Mahadevan M, Crow YJ, Markham AF, Walsh CA, Woods CG. 2002. ASPM is a major determinant of cerebral cortical size. *Nat Genet* 32:316–320.
- Bond J, Roberts E, Springell K, Lizarraga SB, Scott S, Higgins J, Hampshire DJ, Morrison EE, Leal GF, Silva EO, Costa SM, Baralle D, Raponi M, Karbani G, Rashid Y, Jafri H, Bennett C, Corry P, Walsh CA, Woods CG. 2005. A centrosomal mechanism involving CDK5RAP2 and CENPJ controls brain size. *Nat Genet* 37:353–355.
- Bowen PA. 1990. Hutterite syndrome, Bowen Conradi type. In: Buyse ML, editor. *Birth defects encyclopedia*. Dower, USA: Centre for Birth Defects Information Services, Inc. p 883–884.
- Cox J, Jackson AP, Bond J, Woods CG. 2006. What primary microcephaly can tell us about brain growth. *Trends Mol Med* 12:358–366.
- Dobyns WB. 2002. Primary microcephaly: New approaches for an old disorder. *Am J Med Genet* 112:315–317.
- Fenton TR. 2003. A new growth chart for preterm babies: Babson and Benda's chart updated with recent data and a new format. *BMC Pediatr* 3:13.
- Gupta A, Phadke SR. 2001. Bowen-Conradi syndrome in an Indian infant: First non Hutterite case. *Clin Dysm* 10:155–156.
- Hunter WGA, Woerner SI, Montalvo-Hicks LDC, Fowlow SB, Haslam RHA, Metcalf PJ, Lowry RB. 1979. The Bowen Conradi syndrome—A highly lethal autosomal recessive syndrome of microcephaly, micrognathia, low birth weight and joint deformities. *Am J Med Genet* 3:269–279.
- Jackson AP, Eastwood H, Bell SM, Adu J, Toomes C, Carr IM, Roberts E, Hampshire DJ, Crow YJ, Mighell AJ, Karbani G, Jafri H, Rashid Y, Mueller RF, Markham AF, Woods CG. 2002. Identification of microcephalin, a protein implicated in determining the size of the human brain. *Am J Hum Genet* 71:136–142.
- Kelley RI, Robinson D, Puffenberger EG, Strauss KA, Morton DH. 2002. Amish lethal microcephaly: A new metabolic disorder with severe congenital microcephaly and 2-ketoglutaric aciduria. *Am J Med Genet* 112:318–326.
- Lander ES, Botstein D. 1987. Homozygosity mapping: A way to map human recessive traits with the DNA of inbred children. *Science* 236:1567–1570.
- Lowry RB, Innes AM, Bernier FP, McLeod DR, Greenberg CR, Chudley AE, Chodirker B, Marles SL, Crumley MJ, Loredó-Osti JC, Morgan K, Fujiwara TM. 2003. Bowen-Conradi syndrome: A clinical and genetic study. *Am J Med Genet Part A* 120A:423–428.
- Mochida GH, Walsh CA. 2001. Molecular genetics of human microcephaly. *Curr Opin Neurol* 14:151–156.
- Mochida GH, Walsh CA. 2004. Genetic basis of developmental malformations of the cerebral cortex. *Arch Neurol* 61:637–640.
- Peiffer A, Singh N, Leppert M, Dobyns, Carey JC. 1999. Microcephaly with simplified gyral pattern in six related children. *Am J Med Genet* 84:137–144.
- Rosenberg MJ, Agarwala R, Bouffard G, Davis J, Fiermonte G, Hilliard MS, Koch T, Kalikin LM, Makalowska I, Morton DH, Petty EM, Weber JL, Palmieri F, Kelley RI, Schaffer AA, Biesecker LG. 2002. Mutant deoxynucleotide carrier is associated with congenital microcephaly. *Nat Genet* 32:175–179.
- Siebert JR. 1986. Prenatal growth of the median face. *Am J Med Genet* 25:369–379.
- Sztriha L, Johansen JG, Al-Gazali LT. 2005. Extreme microcephaly with agyria-pachygyria, partial agenesis of corpus callosum, and pontocerebellar dysplasia. *J Child Neurol* 20:170–172.
- Woods CG. 2004. Human microcephaly. *Curr Opin Neurobiol* 14:112–117.