

Tina Young Poussaint
Jeremy W. Fox
William B. Dobyns
Rodney Radtke
Ingrid E. Scheffer
Samuel F. Berkovic
Patrick D. Barnes
Peter R. Huttenlocher
Christopher A. Walsh

Periventricular nodular heterotopia in patients with filamin-1 gene mutations: neuroimaging findings

Received: 21 March 2000
Accepted: 8 June 2000

T. Y. Poussaint (✉)
Department of Radiology,
Children's Hospital,
300 Longwood Avenue, Boston,
Massachusetts 02115, USA
e-mail: Tina.Poussaint@TCH.Harvard.edu
Tel.: + 1-617-3556450
Fax: + 1-617-2647120

J. W. Fox · C. A. Walsh
Program in Biological and Biomedical
Sciences, Harvard Medical School, Boston,
Massachusetts, USA

J. W. Fox · C. A. Walsh
Division of Neurogenetics, Department of
Neurology, Beth Israel Deaconess Medical
Center, Harvard Institutes of Medicine,
Boston, Massachusetts, USA

W. B. Dobyns
Department of Human Genetics,
The University of Chicago, Chicago,
Illinois, USA

R. Radtke
Division of Neurology,
Duke University Medical Center, Durham,
North Carolina, USA

I. E. Scheffer · S. F. Berkovic
Department of Neurology,
University of Melbourne,
Austin and Repatriation Medical Centre,
Heidelberg, Australia

Abstract *Background.* The filamin-1 (FLN-1) gene is responsible for periventricular nodular heterotopia (PNH), which is an X-linked dominant neuronal migration disorder. *Objective.* To review the clinical and imaging findings in a series of patients with documented filamin-1 mutations.

Materials and methods. A retrospective review of the medical records and MR studies of a series of patients with PNH and confirmed FLN-1 mutations was done. There were 16 female patients (age range: .67–71 years; mean = 28.6) with filamin-1 gene mutations.

Results. In six of the patients the same mutation was inherited in four generations in one pedigree. In a second pedigree, a distinct mutation was found in two patients in two

generations. In a third pedigree, a third mutation was found in four patients in two generations. The remaining four patients had sporadic de novo mutations that were not present in the parents. Ten patients had seizures, and all patients had normal intelligence. In all 16 patients MR demonstrated bilateral near-continuous PNH. There were no consistent radiographic or clinical differences between patients carrying different mutations.

Conclusion. Patients with confirmed FLN-1 gene mutations are usually female and have a distinctive MR pattern of PNH. Other female patients with this same MR pattern probably harbor FLN-1 mutations and risk transmission to their progeny. This information is important for genetic counseling.

P. D. Barnes
Division of Neuroradiology,
Department of Radiology,
Children's Hospital and Harvard Medical
School, Boston, Massachusetts, USA

P. R. Huttenlocher
Department of Pediatrics,
University of Chicago, Chicago, Illinois,
USA

Table 1 Clinical findings in patients with FLN-1 mutations and subependymal heterotopia (*TC* tonic-clonic, *sz* seizures, *PC* partial complex)

Patient	Age/gender	Seizures type/age at Onset	Family history	Other clinical findings	Intelligence
1	31/F	Atypical absence/12	Daughter	Bicuspid AV, congenital strabismus, short digit	Normal
2	3/F	None	Mother	PDA, congenital strabismus, GI dysmotility	Normal
3	35/F	TCsz/18	No	–	Normal
4	0.7/F	None	No	PDA, brachycephaly, hypertelorism	Normal
5	31/F	TCsz/31	No	–	Normal
6	71/F	Sydenham's chorea in childhood	Multiple	Numerous strokes since age 50	Normal
7	46/F	TCsz/18	Multiple	–	Normal
8	45/F	TCsz/4	Multiple	Stroke age: 41	Normal
9	26/F	TCsz/24	Multiple	–	Normal
10	21/F	TCsz/5	Multiple	Stroke age: 19	Normal
11	2/F	None	Multiple	PDA	Normal
12	34/F	None	None	PDA, Unsteadiness, dizzy episodes	Normal
13	53/F	None	Daughters	–	Normal
14	16/F	TCsz/16.5	Mother/sisters	–	Normal
15	20/F	PC/17	Mother/sisters	–	Normal
16	23/F	PC/23	Mother/sisters	–	Normal

Introduction

Periventricular nodular heterotopia (PNH) is a disorder of neuronal migration characterized by subependymal gray matter nodules in a periventricular location [1–5]. It is an X-linked dominant disorder presenting primarily in females in whom subsets of neurons fail to migrate and persist as nodules lining the ventricular surface [6]. Recently a gene for PNH has been identified as filamin-1 (FLN-1; also known as FLNA, actin-binding protein 280, ABP-280) [7]. FLN-1 is an actin-cross-linking phosphoprotein expressed in nonmuscle cells originally identified from motile blood cells [8–11]. It has a high level of expression in the developing cortex and is required for neuronal migration in the cerebral cortex and is subsequently downregulated in the adult [6, 7]. The shortage of males in pedigrees with FLN-1 mutations suggests that FLN-1 is required for normal embryonic development, perhaps in developing blood vessels.

The purpose of this paper was to review the clinical findings and neuroimaging features in a group of patients identified with FLN-1 gene mutations and PNH.

Materials and methods

Clinical history and genetic testing

Over a 5-year period, 65 patients with PNH were referred for laboratory genetic analysis. These patients were referred for genetic testing after imaging studies had confirmed the presence of PNH. In each of these patients, 6 of the 48 exons of FLN-1 were analyzed for mutations by polymerase chain reaction (PCR) amplification of each exon. Sixteen patients were identified with FLN-1 gene mutations. The remaining patients await further genetic testing. The medical records were analyzed for clinical histories.

Neuroimaging

Initial imaging studies were available in all 16 patients and consisted of MR in 16 patients and CT in 3 patients. MR examinations were performed on a 1.5-T system in 14 patients and a 1.0T system in 2 patients. Imaging parameters included 5-mm slices with an intersection gap of 1 mm and a 256 × 192 matrix for sagittal T1-weighted conventional spin-echo images (500/14/1 [TR/TE/excitations]). In eight patients, fast spin-echo (FSE) axial proton density-weighted (3500–4000/17/1) and fast spin-echo axial T2-weighted (3500–4000/102/1) were obtained with a section thickness of 5 mm and a gap of 2.0 mm, and a 256 × 192 matrix. In the remaining eight patients conventional spin-echo dual echo images were obtained (2000/20–80) with a section thickness of 5 mm and a gap of 2.5 mm, and a 256 × 192 matrix. Contrast material was administered intravenously in two patients at a dosage of 0.1 mmol/kg followed by axial and/or coronal T1 images. In addition, in five patients axial T1, coronal FSE proton density, or FSE T2 images

Table 2 Imaging findings in patients with FLN-1 mutations and subependymal heterotopia (*MCM* mega cisterna magna, *AH* anterior horn, *B* body, *T* trigone, *O* occipital)

Patient	Location	Location	Extent	Size	Corpus callosum	Other anomalies
1	Bilateral	AH,T,B,O	Diffuse, continuous	5 mm	Normal	Prominent cerebellar folia, hypoplasia of inferior vermis, prominent cisterna magna, radiating bands of neurons
2	Bilateral	AH,T,B,O	Diffuse, continuous	5 mm	Normal	R frontal subcortical br T2 focus
3	Bilateral	AH,T,B,O	Diffuse, continuous	8 mm	Hypoplasia of splenium	MCM; nodular heterotopia, L corona radiata with radiating bands
4	Bilateral	AH,T,B,O	Diffuse, continuous	8 mm	–	Mild prominence of lateral ventricles
5	Bilateral	AH,T,B	Discontinuous	9 mm	–	MCM
6	Bilateral	AH,T,B,O	Diffuse, continuous	6 mm	Normal	–
7	Bilateral	AH,T,B,O	Diffuse, continuous	5 mm	Normal	Mild prominence of lateral ventricles
8	Bilateral	AH,T,B,O	Diffuse, continuous	7 mm	Normal	–
9	Bilateral	AH,T,B,O	Diffuse, continuous	8 mm	Normal	–
10	Bilateral	AH,T,B,O	Diffuse, continuous	7 mm	Normal	–
11	Bilateral	AH,T,B,O	Diffuse, continuous	6 mm	Normal	–
12	Bilateral	AH,T,B,O	Diffuse, continuous	8 mm	Normal	MCM
13	Bilateral	AH,B,T	Discontinuous	8 mm	Normal	–
14	Bilateral	AH,B,T,O	Diffuse, continuous	8 mm	Normal	Radiating bands of heterotopic neurons in white matter
15	Bilateral	AH,B,T	Discontinuous	9 mm	Normal	–
16	Bilateral	AH,B,T,O	Diffuse, continuous	10 mm	Normal	–

were also obtained. 3D spoiled grass (SPGR) images were obtained in two patients with 1.5- or 2.5-mm section thickness. Axial 5-mm CT sections were obtained without contrast in three patients.

Results

Clinical history and genetic testing

There were 16 patients identified with FLN-1 gene mutations and PNH (Tables 1, 2). All were female with ages ranging from .67 to 71 years (mean 28.6 years; median 28.5 years). The ages of ten patients at onset of seizures ranged from 4 to 31 years (mean 16.9 years; median 17.5 years). The seizures were tonic-clonic in seven, partial complex in two, and atypical absence in one. One patient had Sydenham's chorea, which developed in childhood, that subsequently resolved. On follow-up the patients with seizures were stable on treatment. None of the patients had clinically significant mental retardation, and many of them were highly intelligent college graduates, although formal IQ testing was not done.

In one pedigree, six patients inherited the same mutation in four generations. This family was previously reported [7, 12] (Fig. 1). This mutation was a cytosine to thymine (C to T) change at base pair 544, which caus-

es protein truncation at amino acid 192. In a second pedigree, the same mutation was found in two patients in two generations. This mutation was a T to C change at the splice donor of exon 4, which causes the missplicing of exon 4 and presumably results in an unstable mRNA or protein truncation. In a third pedigree, a third mutation was found in four patients in two generations (Fig. 2). This mutation was an adenine to guanine (A to G) change at the splice acceptor of exon 7, which causes missplicing of intron 6 and protein truncation. The remaining four patients had mutations that were not present in any parents by testing, and there was no evidence of seizures or PNH in prior generations. These patients were inferred to represent de novo mutations. In one patient, the mutation was a C to G change at the splice acceptor of exon 4, which causes missplicing of intron 3 and protein truncation. In the second patient, the mutation was a G to A change at the splice donor of exon 2, which causes missplicing of intron 2 and protein truncation. In the third patient, the mutation was a GGCC deletion at base pair 287–291, which causes a frameshift of protein translation and protein truncation after amino acid 96. In the fourth patient, the mutation was a C to T change at base pair 699, which causes truncation at amino acid 230. There were no consistent radiographic or clinical differences between patients carrying different mutations.

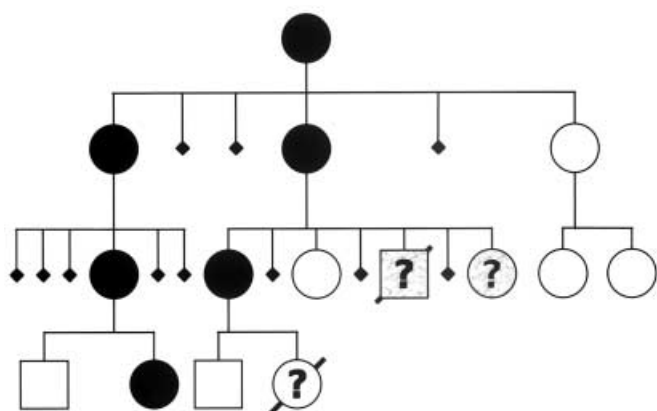


Fig. 1 Largest reported pedigree of four generations of affected female patients with PNH. Figure modified from previous article [12]. Individuals with clinical features that might suggest PNH are indicated by shading while unshaded symbols with question marks indicate no knowledge of phenotype (males squares, females circles, spontaneous abortions or stillbirths smaller symbols, unknown or uncertain gender diamonds)

Additional conditions found in these patients consisted of patent ductus arteriosus requiring surgical repair in four, strokes at an early age in three (one at less than 20 years and two at 20–60 years), congenital strabismus in two, a bicuspid aortic valve in one, short digits in one, and gastrointestinal dysmotility in one. In one patient there was mild brachycephaly, bitemporal prominence, downslanting palpebral fissures, and marked hypertelorism.

In the largest reported pedigree [12], there was a high prevalence of miscarriage. One son of a woman with PNH died at age 7 days from multiple systemic hemorrhages. At postmortem examination, severe arrest of myeloid and erythroid differentiation was found in the bone marrow along with lymphoid depletion in the thymus. This patient had a FLN-1 gene mutation. It is unclear if he had nodular periventricular heterotopia.

Neuroimaging

On MR and CT, all affected patients had subependymal nodules. These nodules were isodense and isointense to gray matter on CT (Fig. 3 d) and MR, respectively. The nodules measured from 5 to 10 mm (mean = 7 mm) in maximum diameter. In the majority of cases the heterotopia were diffuse and continuous around the lateral ventricles and involved the frontal horns, trigones, bodies, and occipital horns (Figs. 3 b, 4 b, 5 b, c). The PNH were diffuse and continuous in 13 patients and discontinuous in 3 involving the anterior horns, bodies, and trigones of the lateral ventricles bilaterally (Fig. 4 a). None of the heterotopia was found in the temporal horns of

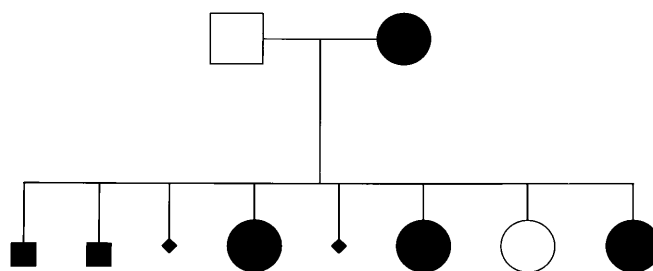


Fig. 2 Pedigree demonstrating four female patients in two generations with PNH

the lateral ventricles. In all patients the cortical gray matter was normal in appearance and thickness. There were radiating bands of heterotopic neurons in the white matter in three patients. In three patients there was a mega cisterna magna anomaly (Fig. 3 c). This was associated with bony scalloping in one patient. There was prominence of the cerebellar folia with hypoplasia of the inferior vermis in one patient (Fig. 5 a). In two patients there was dysgenesis of the corpus callosum, including foreshortening of the corpus callosum and hypoplasia of the splenium (Fig. 3 c). The ventricles were normal in size in 14 and were mildly prominent in 2.

Chronic infarction was seen in three patients of the same pedigree. They were multiple, bilateral, subcortical, and cortical in one patient. A right middle cerebral artery infarction was seen in a second patient. A right frontoparietal cortical infarct and an internal capsule infarct were present in a third patient.

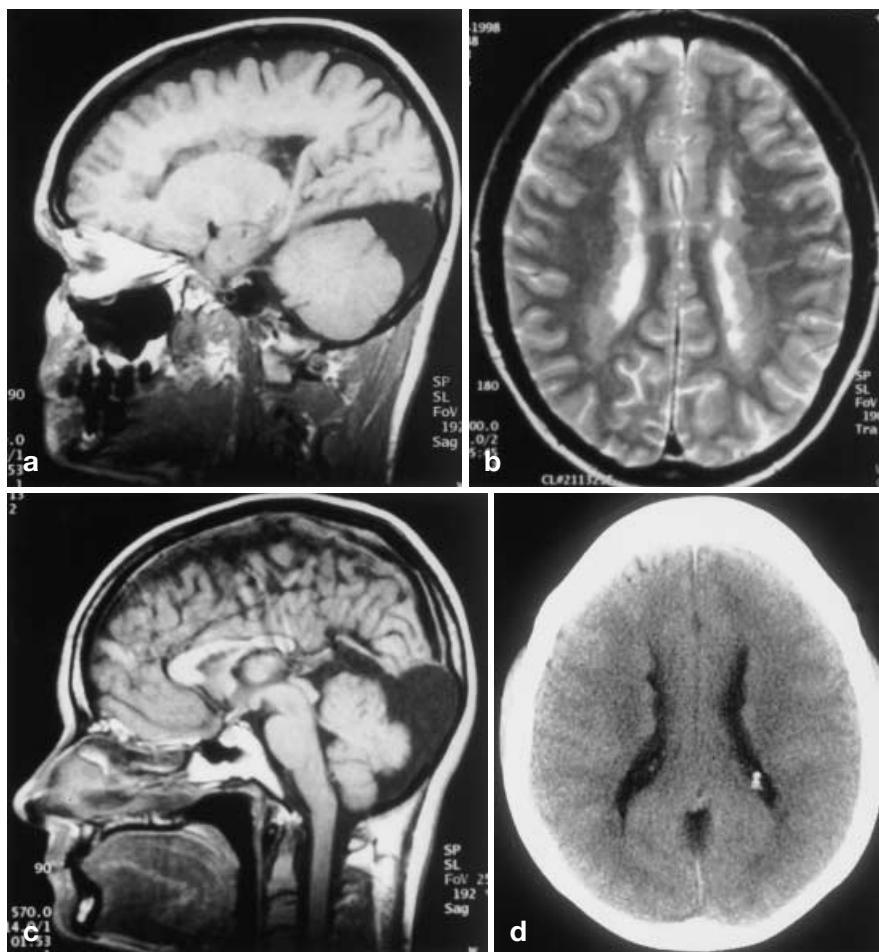
Tiny nonspecific foci of T2 hyperintensity measuring 3 mm were present within the cerebral white matter in two patients.

Discussion

Genetic aspects and clinical history

The human FLN-1 gene is located on the X chromosome. FLN-1 encodes an actin-binding protein. Mutations in the gene for this protein as seen in this study are associated with PNH (Fig. 6). Further mutations may be discovered given the large size of the gene when complete mutational analysis of the remaining patients is completed. The protein controls the cross-linking of actin filaments important for neuronal migration and likely provides a link between membrane receptors and the actin cytoskeleton [7, 13]. It is developmentally regulated in the brain and has high expression during neuronal migration with subsequent downregulation in adulthood. FLN-1 has been found in the migrating and postmigrating neurons in the brain and is expressed during radial migration [7].

Fig. 3a-d Thirty-five-year-old woman with PNH (patient 3; Tables 1, 2). Sagittal T1 image (570/14/1)(TR/TE/no. excitations)(a) and axial FSE T2 image (4000/85/2)(b) demonstrate diffuse continuous PNH isointense to gray matter on all sequences and radiating bands of heterotopic neurons in the white matter. Sagittal T1 image (570/14/1)(c) demonstrates hypoplasia of splenium of corpus callosum and mega cisterna magna in the same patient. Axial CT(d) shows isodense PNH



In our series, all of the patients with FLN-1 gene mutations were female. This concurs with the literature, where the majority of patients with PNH are female [1, 4, 6, 12, 14]. In the family previously reported by Huttenlocher et al. [12] (also included in this study) there was a high rate of spontaneous abortion, including 11 miscarriages in 5 women with nonviability of the affected males. It is suspected that most males with PNH gene mutations die during early embryogenesis [6]. Some males have been reported with radiographic characteristics similar to the patients reported here [4, 15–17]. One of these males had a duplication of Xq28, but it is unknown whether the others harbor FLN-1 mutations [16, 17].

The majority (75%) of the patients with PNH in this study occurred in affected pedigrees. However, this number is highly dependent on a single pedigree of six affected individuals, representing by far the largest pedigree of PNH ever reported. Therefore, patients in this series may be biased toward inherited cases, and a larger series will probably show a higher proportion of spontaneous mutations. As in previous reports, PNH has been

associated with seizures. These are commonly mixed partial or tonic-clonic seizures, and the majority presented in the second or third decade of life [1, 12, 14, 15]. The majority of these patients have normal intelligence [1, 6].

There were no consistent radiographic or clinical differences between patients carrying different mutations, presumably because the mutations truncate or disrupt the FLN-1 protein, therefore making it completely non-functional.

FLN-1 has a role in hemostasis and vascular remodeling. It binds to tissue factor that initiates the extrinsic coagulation cascade, and the binding of tissue factor with FLN-1 is associated with actin filament reorganization [18]. The high incidence of PDA and bicuspid aortic valve in these patients relative to the general population may relate to the role of FLN-1 in vascular remodeling [7, 19]. FLN1 also has been found to act in platelets to couple glycoprotein Iba, which is part of the receptor for thrombin, and von Willebrand's factor important for platelet aggregation to the actin cytoskeleton, which plays a role in thrombus formation [20, 21].

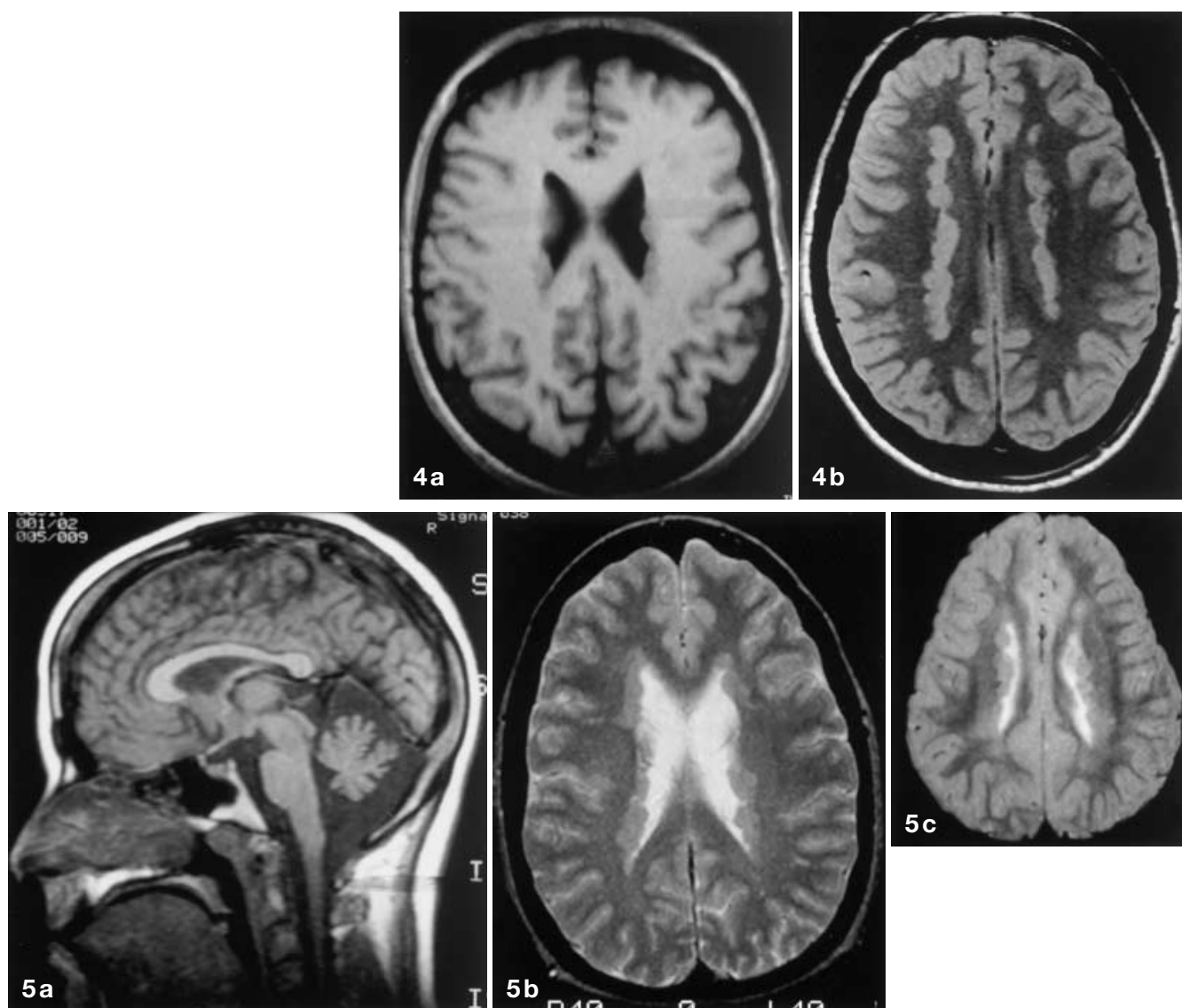


Fig. 4 a, b Fifty-three-year-old woman with PNH and her 16-year-old daughter (patients 13 and 14; Tables 1, 2; Fig. 2). Axial T1 image (570/14/1)(a) demonstrates discontinuous PNH in the mother. Axial FSE PD image (3000/20/1)(b) demonstrates diffuse, contiguous PNH with a few radiating bands of heterotopic neurons in the white matter of her daughter (patient 14)

Fig. 5 a–c Thirty-one-year-old woman with PNH and her 3-year-old daughter (patients 1 and 2; Tables 1, 2). Sagittal T1 image (400/16/1) (a) demonstrates prominent cerebellar folia and hypoplasia of the inferior vermis. Axial SE T2 image (2000/80/.75) (b) demonstrates diffuse, continuous PNH with a few radiating bands of heterotopic neurons in the white matter. Axial SE T2 image (2000/80/.75) (c) demonstrates diffuse, continuous PNH in her daughter (patient 2)

This likely plays a role in the occurrence of cerebral infarction in these patients.

Neuroimaging

In all patients the PNH are isodense and isointense to cortical gray matter on CT and MR, respectively, and did not enhance with gadolinium [5, 12, 22–24]. These indent the lateral ventricles and are often continuous, involving the frontal horns, trigones, bodies, and occipital horns of the lateral ventricles. The diagnosis of PNH is best made with MR and must be distinguished from the periventricular nodules in tuberous sclerosis. In tuberous sclerosis, there are subependymal and cortical tubers, white matter lesions, and subependymal giant cell astrocytoma. The mega cisterna magna is defined

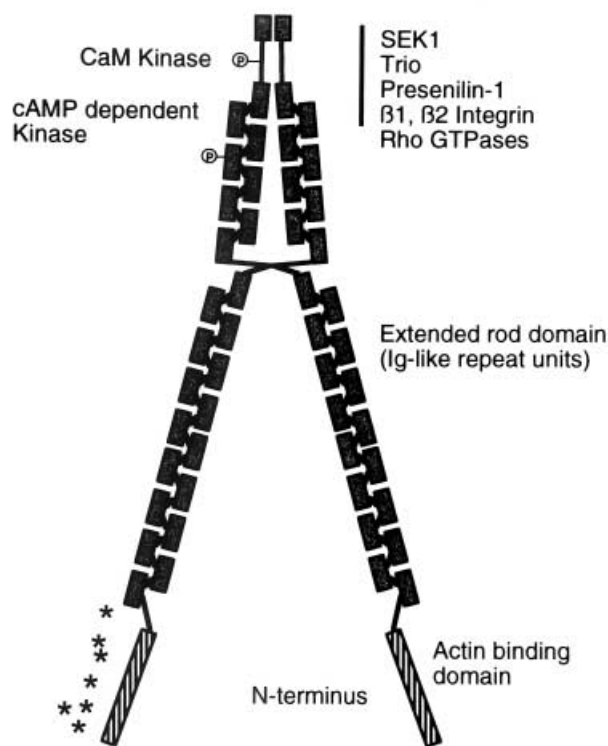


Fig. 6 Diagram of structure of filamin-1 demonstrating the actin-binding protein at the N-terminus. Asterisks reflect the site of protein truncation for each mutation in this study

as a prominent CSF space posterior to the cerebellum without vermian agenesis or significant mass effect and is part of the Dandy Walker spectrum [25]. The association of PNH and mega cisterna magna has been previously described in one family by Oda et al. [26]. Dysgenesis of the corpus callosum was previously re-

ported in patients with PNH by Barkovich and Kjos [1] and Cho et al. [15]. The association between agenesis of the corpus callosum and gray matter heterotopias has also been reported [27]. The role of the filamin-1 gene in the development of this anomaly is unknown. No cortical abnormalities were identified, which may be due in part to the fact that high-resolution volume acquisition was performed in only two patients. However, three patients had additional heterotopic neurons consisting of radiating bands in the white matter, suggesting transcortical malformations of cortical development.

Conclusion

Patients with confirmed FLN-1 gene mutations have a distinctive MR pattern of PNH and are usually female. Although there are undoubtedly other genes that cause PNH, filamin-1 mutations appear to cause a characteristic appearance radiographically, as well as a typical clinical picture of seizures with onset in childhood or young adulthood and mild or no cognitive difficulties. Other patients, particularly females with this same MR pattern of PNH, probably harbor FLN-1 mutations. These patients risk the transmission of PNH and epilepsy to their progeny. Such information is important for genetic counseling. At present it appears that PNH will be transmitted in a dominant fashion from an affected female to one-half of her female children. In principle, filamin-1 mutations would be passed to one-half of the male children of an affected female as well, although some or all of the males carrying the mutation may be miscarried.

Acknowledgements We would like to thank Virginia Grove for manuscript preparation and Donald Sucher for photography.

References

1. Barkovich AJ, Kjos BO (1992) Gray matter heterotopias: MR characteristics and correlation with developmental and neurologic manifestations. *Radiology* 182: 493–499
2. Barkovich A, Kuzniecky R, Dobyns W, et al (1996) A classification scheme for malformations of cortical development. *Neuropediatrics* 27: 59–63
3. Dobyns WB, Andermann E, Andermann F, et al (1996) X-linked malformations of neuronal migration. *Neurology* 47: 331–339
4. Dubeau F, Tampieri D, Lee N, et al (1995) Periventricular and subcortical nodular heterotopia. A study of 33 patients. *Brain* 118: 1273–1287
5. Smith AS, Weinstein MA, Quencer RM, et al (1988) Association of heterotopic gray matter with seizures: MR imaging. *Work in progress. Radiology* 168: 195–198
6. Eksioğlu YZ, Scheffer IE, Cardenas P, et al (1996) Periventricular heterotopia: an X-linked dominant epilepsy locus causing aberrant cerebral cortical development. *Neuron* 16: 77–87
7. Fox J, Lamperti E, Eksioğlu Y, et al (1998) Mutations in filamin 1 arrest migration of cerebral cortical neurons in human periventricular heterotopia. *Neuron* 21: 1315–1325
8. Gorlin J, Yamin R, Egan S, et al (1990) Human endothelial actin-binding protein (ABP-280, nonmuscle filamin): a molecular leaf spring. *J Cell Biol* 111: 1089–1105
9. Hartwig J, Tyler J, Stossel T (1980) Actin-binding protein promotes the bipolar and perpendicular branching of actin filaments. *J Cell Biol* 87: 841–848
10. Hartwig J, Shevlin P (1986) The architecture of actin filaments and the ultrastructural location of actin-binding protein in the periphery of lung macrophages. *J Cell Biol* 103: 1007–1020
11. Hartwig J (1992) Mechanisms of actin rearrangements mediating platelet activation. *J Cell Biol* 106: 1525–1538

12. Huttenlocher PR, Taravath S, Mojta-hedi S (1994) Periventricular heterotopia and epilepsy. *Neurology* 44: 51–55
13. Glogauer M, Arora P, Chou D, et al (1998) The role of actin-binding protein 280 in integrin-dependent mechano-protection. *J Biol Chem* 273: 1689–1698
14. Raymond AA, Fish DR, Stevens JM, et al (1994) Subependymal heterotopia: a distinct neuronal migration disorder associated with epilepsy. *J Neurol Neurosurg Psychiatry* 57: 1195–1202
15. Cho WH, Seidenwurm D, Barkovich AJ (1999) Adult-onset neurologic dysfunction associated with cortical malformations. *AJNR* 20: 1037–1043
16. Dobyns WB, Guerrini R, Czapansky-Beilman DK, et al (1997) Bilateral periventricular nodular heterotopia with mental retardation and syndactyly in boys: a new X-linked mental retardation syndrome. *Neurology* 49: 1042–1047
17. Fink JM, Dobyns WB, Guerrini R, et al (1997) Identification of a duplication of Xq28 associated with bilateral periventricular nodular heterotopia. *Am J Hum Genet* 61: 379–387
18. Ott I, Fischer EG, Miyagi Y, et al (1998) A role for tissue factor in cell adhesion and migration mediated by interaction with actin-binding protein 280. *J Cell Biol* 140: 1241–1253
19. Mullins C, Pagotto L (1998) Patent ductus arteriosus. In: Garson A, Bricker J, Fisher D, et al (eds) *The science and practice of pediatric cardiology*, vol 1. Williams and Wilkins, Baltimore, p 1181
20. Meyer SC, Zuerbig S, Cunningham CC, et al (1997) Identification of the region in actin-binding protein that binds to the cytoplasmic domain of glycoprotein I β . *J Biol Chem* 272: 2914–2919
21. Okita JR, Pidard D, Newman PJ, et al (1985) On the association of glycoprotein I β and actin-binding protein in human platelets. *J Cell Biol* 100: 317–321
22. Canapicchi R, Padolecchia R, Puglioli M, et al (1990) Heterotopic gray matter. Neuroradiological aspects and clinical correlations. *J Neuroradiol* 17: 277–287
23. Hayden S, Davis K, Stears J, et al (1987) MR imaging of heterotopic gray matter. *J Comput Assist Tomogr* 11: 878–879
24. Barkovich AJ, Lyon G, Evrard P (1992) Formation, maturation, and disorders of white matter. *AJNR* 13: 447–461
25. Strand RD, Barnes PD, Poussaint TY, et al (1993) Cystic retrocerebellar malformations: unification of the Dandy-Walker complex and Blake's pouch cyst. *Pediatr Radiol* 23: 258–260
26. Oda T, Nagai Y, Fujimoto S, et al (1993) Hereditary nodular heterotopia accompanied by mega cisterna magna. *Am J Med Genet* 47: 268–271
27. Barth PG (1987) Disorders of neuronal migration. *Can J Neurol Sci* 14: 1–16